

Activity of pan-RAF inhibitor DAY101 in a pediatric patient with a recurrent spindle cell sarcoma harboring a novel *SNX8-BRAF* gene fusion

Katharine Offer,¹ Michael McGuire,² Eleni Venetsanakos,³ Samuel C. Blackman,³ Kunchang Song,⁴ Michael Goldfischer,⁴ Michael C. Cox³

¹Children's Cancer Institute, Joseph M. Sanzari Children's Hospital, Hackensack Meridian Health, Hackensack, NJ; ²Department of Radiology, Hackensack Meridian School of Medicine, Hackensack, NJ; ³Day One Biopharmaceuticals, South San Francisco, CA; ⁴Department of Pathology, Hackensack Meridian Health, Hackensack, NJ, United States
Poster #: P250

Background

- Genomic alterations resulting in dysregulation of the RAS-RAF-MEK-ERK (MAPK) pathway have been described in many different types of pediatric and adult malignancies and include:
 - Activating point mutations of *BRAF*²
 - BRAF* gene fusions that drive constitutive activation of the pathway through RAS-independent *BRAF* dimers²
 - In-frame *BRAF* deletions³
- BRAF* fusions and activating mutations have recently been reported in mesenchymal tumors with an infantile fibrosarcoma (IFS)-like morphology⁴
- DAY101 (TAK-580, MLN2480, or BILB-024) is an oral, selective, central nervous system-penetrant, type II pan-RAF inhibitor that is in clinical development for patients with cancers harboring an activating *BRAF* alteration
- In biochemical assays, DAY101 demonstrated potency against *BRAF* V600E mutation, wild-type *BRAF* and wild-type CRAF. DAY101 can inhibit both monomeric and dimeric RAF:
 - Preclinical *in vitro* studies have shown that DAY101 does not induce paradoxical activation of MAPK signaling in tumor models driven by the *KIAA1549-BRAF* gene fusion⁵
- In an ongoing pediatric phase 1 study, DAY101 was well tolerated and induced rapid and durable responses in 5 of 8 pediatric patients with low-grade glioma harboring a *BRAF* or *CRAF* fusion (3 partial responses and 2 complete responses, based on response assessment in neuro-oncology criteria)⁶
- DAY101 was granted **breakthrough therapy designation** by the U.S. Food and Drug Administration (FDA) for the treatment of pediatric patients with an advanced low-grade glioma harboring an activating *RAF* alteration, who require systemic therapy and who have either progressed following prior treatment or have no satisfactory alternative treatment options
- DAY101 has also received **orphan drug designation** from the FDA and the European Commission for the treatment of malignant glioma
- We explored whether DAY101 might be an effective treatment option for a child with recurrent spindle cell sarcoma harboring a novel *SNX8-BRAF* gene fusion who had exhausted all treatment options including trametinib, a MEK inhibitor

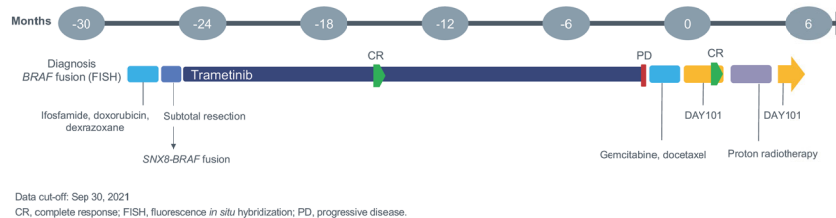
Methods

- BRAF* fluorescence *in situ* hybridization (FISH) analysis was undertaken in a research setting using a break-apart assay incorporating bacterial artificial chromosome probes
- Whole exome sequencing was performed on DNA extracted from normal (buccal swab) and tumor (snap frozen) tissue samples (Laboratory of Personalized Genomic Medicine, Department of Pathology and Cell Biology, Columbia University Irving Medical Center)
- Transcriptome sequencing was performed on RNA isolated from the frozen tumor sample
- Targeted next-generation sequencing to screen for gene fusion events was performed on RNA extracted from the frozen tumor tissue using anchored multiplex PCR technology (Genomic Testing Cooperative, Irvine, CA)
- The pan-RAF inhibitor DAY101 was administered once weekly at a dose of 420 mg/m² in 28-day cycles on a compassionate use basis

Case description

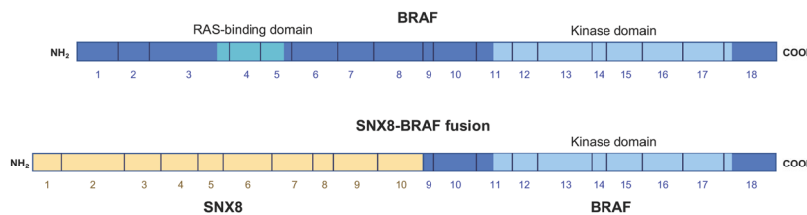
- A male patient, aged 5 years, presented with a one-week history of fever, cough, and respiratory distress
- Following worsening shortness of breath and tachypnea, MRI revealed an 11.2 x 9.4 x 11.9 cm dominant right lower hemithorax mass that was partially encasing the aorta, and likely arising from the posterior mediastinum
- Biopsy of the mediastinal mass revealed a diagnosis of spindle cell sarcoma and FISH indicated that the tumor harbored a *BRAF* gene fusion
- PET/CT showed a hypermetabolic supraclavicular node of concern in relation to metastatic disease as well as hypermetabolic right-sided pleura and subcarinal lymph nodes
- The patient's treatment history is summarized in **Figure 1**
- He received 3 cycles of ifosfamide, doxorubicin, and dexrazoxane as initial systemic therapy
 - Subsequent chest CT scan showed an interval decrease in the size of the right hemithoracic mass and associated pleural effusion
 - The patient underwent a right thoracotomy with subtotal resection of the right chest mass, leaving a 2.1 x 2.7 cm residual soft tissue mass
- Whole exome/transcriptome sequencing of the tumor revealed a novel *SNX8-BRAF* gene fusion, with breakpoints 3' to exon 10 of *SNX8* and 5' to exon 9 of *BRAF* (**Figure 2**)

Figure 1. Treatment summary



- As the *SNX8-BRAF* fusion was deemed potentially to be a MAPK pathway activating alteration, trametinib treatment was started:
 - Following the first month of treatment, the size of residual tumor reduced and hypervascularity resolved
 - CT was repeated 2 months later, and showed no evidence of measurable tumor at the primary site
 - However, several months later, CT showed a new recurrence of a 4.0 x 3.7 x 4.6 cm left posterior mediastinal mass extending circumferentially around the aorta and impressing on the left atrium and pulmonary veins as well as abutting the T7-T8 disc space
- Pending the results of targeted RNA-based next-generation sequencing to rescreen the tumor for gene fusion events, the patient started gemcitabine and docetaxel as second-line therapy for recurrent disease (**Figure 1**):
 - Following 2 cycles of treatment, there was no objective response on imaging and symptoms persisted
- Molecular test results reconfirmed the presence of an *SNX8-BRAF* fusion:
 - The patient was not considered to be eligible for an ERK inhibitor clinical trial as the novel fusion was not detected in the trial-specified panel
- As the tumor had likely developed resistance to MEK inhibition, treatment with pan-RAF inhibitor DAY101 was initiated under a compassionate use protocol

Figure 2. Structure of the *SNX8-BRAF* fusion protein



The structure of the canonical *BRAF* protein sequence (UniProtKB - P15056 [*BRAF_HUMAN*]; <https://www.uniprot.org/uniprot/P15056>) and the predicted *SNX8-BRAF* fusion protein, including functional domains are shown. The *SNX8* and *BRAF* exons, from which the protein sequences are derived, are represented by the numbers below the bars. This rearrangement is predicted to replace the N-terminal regulatory domain of *BRAF* with almost the entire *SNX8* sequence, while leaving the *BRAF* kinase domain intact.

Results

- Following 2 cycles of DAY101, symptoms had resolved, and an MRI scan showed no evidence of measurable disease at the site of previously visualized tumor (**Figure 3**)
- A week after a complete response was documented, DAY101 was stopped and the patient underwent a course of definitive proton radiotherapy, receiving a total dose of 6660 cGEG in 37 fractions
- DAY101 treatment was subsequently resumed after radiotherapy and follow-up is ongoing
- After the first dose of DAY101, the patient experienced grade 2 rash, which resolved in a day following a dose of diphenhydramine
- Radiotherapy-related adverse events included hyperpigmentation overlying the spine on the upper back with no skin breaks, and mild dysphagia

Figure 3. Activity of DAY101

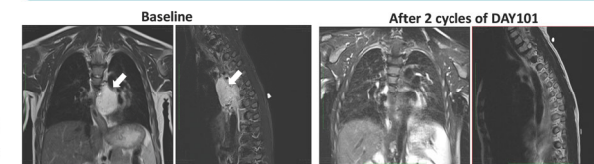


Figure 3. Magnetic resonance imaging (MRI) revealed a mediastinal mass extending circumferentially around the aorta and impressing on the left atrium and pulmonary veins as indicated by white arrows in AP and lateral views. Following 2 cycles of treatment with DAY101, MRI scans revealed only a trace of non-enhancing soft tissue surrounding the descending thoracic aorta.

Conclusions

- The rapid and durable response to DAY101 in this patient indicates that the novel *SNX8-BRAF* gene fusion is a targetable oncogenic driver
- DAY101 is a potentially effective treatment in pediatric patients with soft tissue sarcomas harboring *BRAF* gene fusions and warrants further investigation in other *BRAF* fusion-driven solid tumors
- Tumors with IFS-like morphology should undergo comprehensive genomic profiling to identify novel oncogenic fusions
- DAY101 is currently being investigated in a phase 2 trial for the treatment of *BRAF*-altered, relapsed or progressive low-grade glioma in patients 6 months to 25 years of age (FIREFLY-1, NCT04775485):
 - Plan to include patients with extracranial *RAF*-altered tumors in 2022
- A phase 1/2 trial to evaluate DAY101 in combination with the MEK1 pimasertib to treat solid tumors with MAPK pathway aberrations is planned

References

- Davies H, et al. *Nature*. 2002;417:949-54.
- Ross JS, et al. *Int J Cancer*. 2016;138:881-90.
- Chen SH, et al. *Cancer Discov*. 2016;6:300-15.
- Penning AJ, et al. *Mod Pathol*. 2021;34:1530-40.
- Sun Y, et al. *Neuro Oncol*. 2017;19:774-85.
- Wright K, et al. *Neuro Oncol*. 2020;22(Suppl 2):346, and associated presentation.

